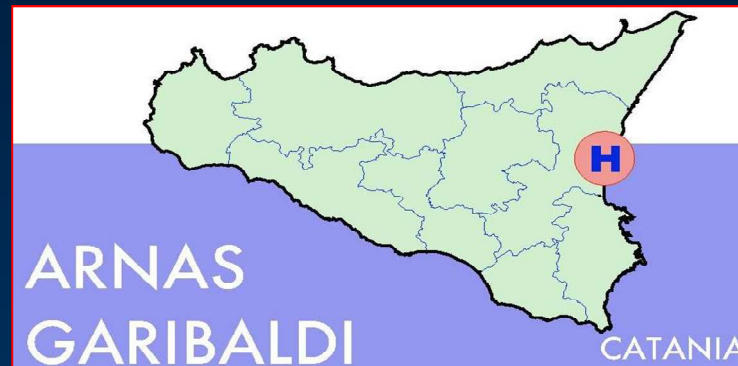

# Azienda Ospedaliera di Rilievo Nazionale e di Alta Specializzazione Garibaldi Catania



Unità Operativa Complessa di Oftalmologia

*Direttore: Dott. Antonio Rapisarda*

The background image is an endoscopic view of a glaucoma surgery site. It shows the iris, which is a textured, brownish structure, and a surgical instrument, likely a microhook, which is a thin, curved metal tool used to manipulate the iris. The instrument is positioned near the iris, and the overall scene is illuminated with a blueish light, typical of endoscopic surgery.

# **Cy-Pass: nuova tecnica nella chirurgia del glaucoma**

**D. Lombardo L. Rapisarda G. Pennisi**

# Premesse

## Chirurgia del glaucoma

Chirurgia perforante

*Gold Standard*

Trabeculectomia

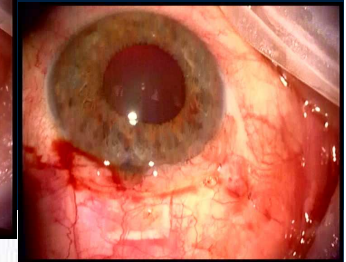
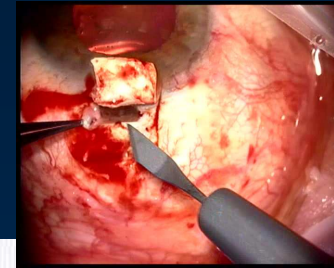
Trabeculectomia + MMC / 5FU

Chirurgia non perforante

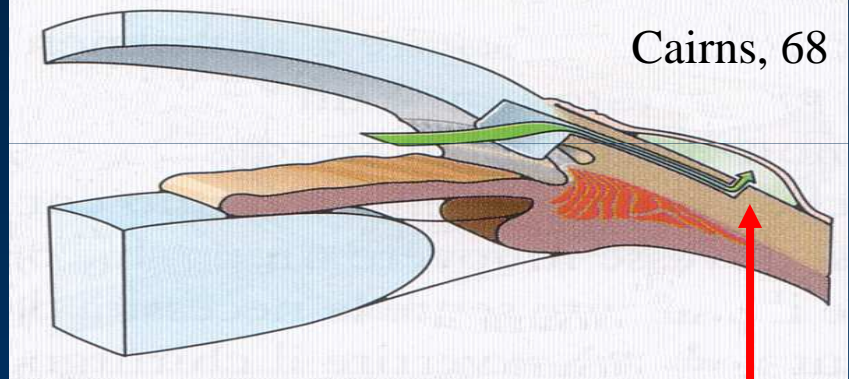
Viscocanalostomia

Sclectomia profonda

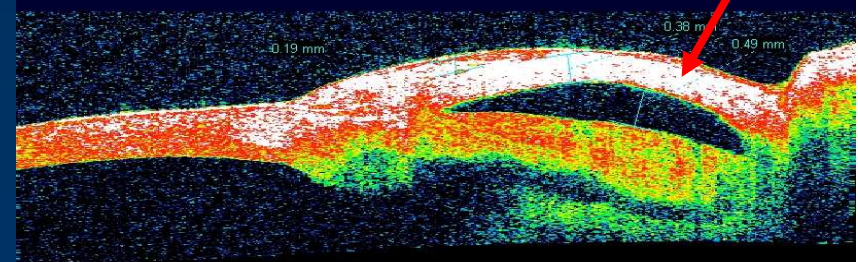
Impianto di protesi drenanti

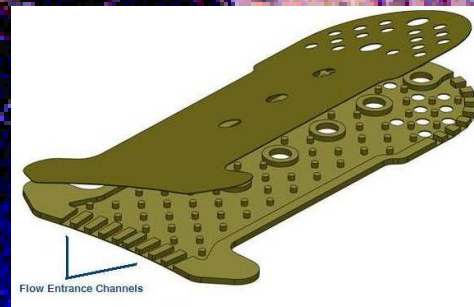
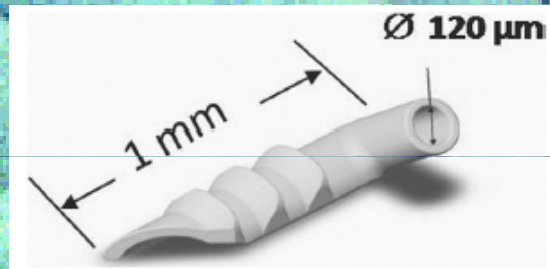


Cairns, 68



Bozza filtrante

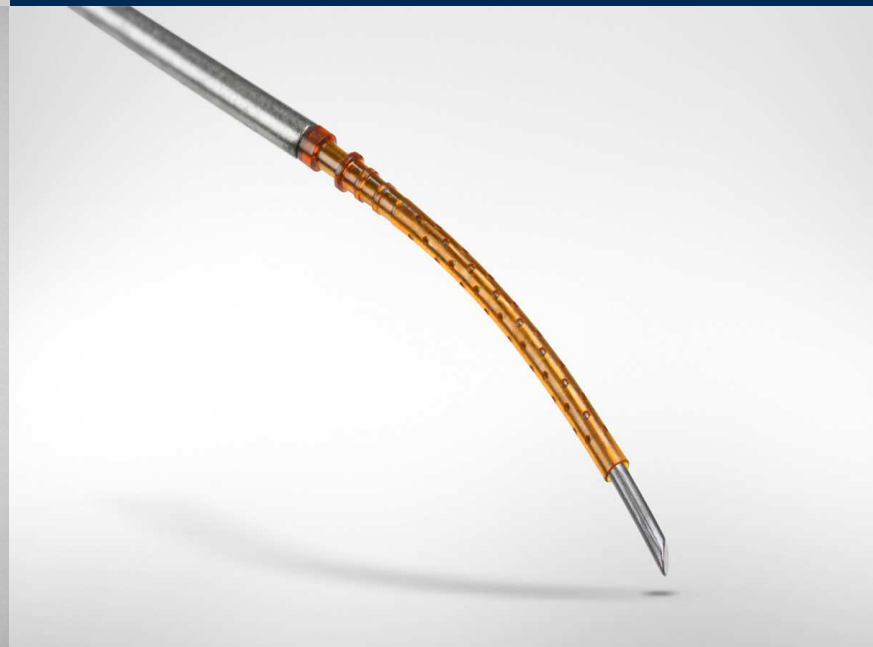
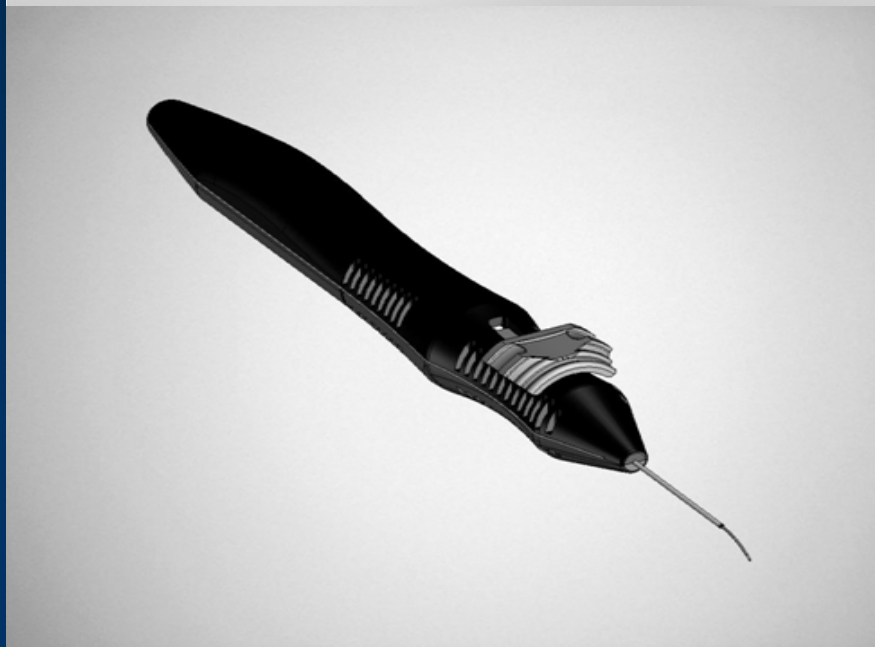



Cypass



CyPass  
Transcend Medical CA  
Device tubulare in poliimide  
dotato di microfori  
Lunghezza 6mm  
Lume 300 $\mu$



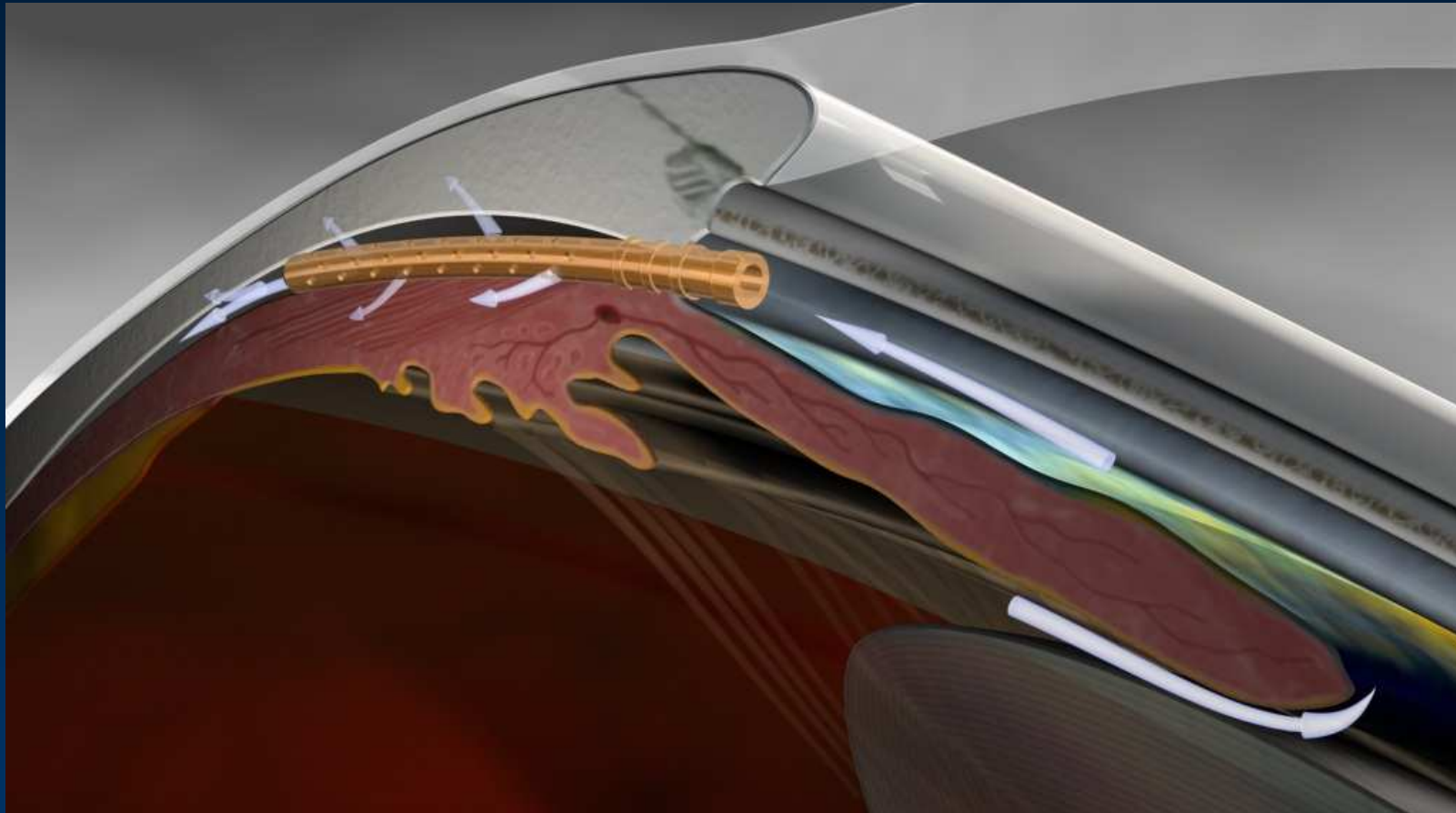
## Via di deflusso Uveo-sclerale



L'umore acqueo passa nello spazio supracoroideale per essere assorbito dalla vascolarizzazione coroideale e attraverso la sclera.

***GRADIENTE PRESSORIO***

## Via di deflusso Uveo-sclerale



Formazione e mantenimento di ciclodiastasi



**Indicazione:** Glaucoma angolo aperto, primario e secondario

Rischio fallimento trab.

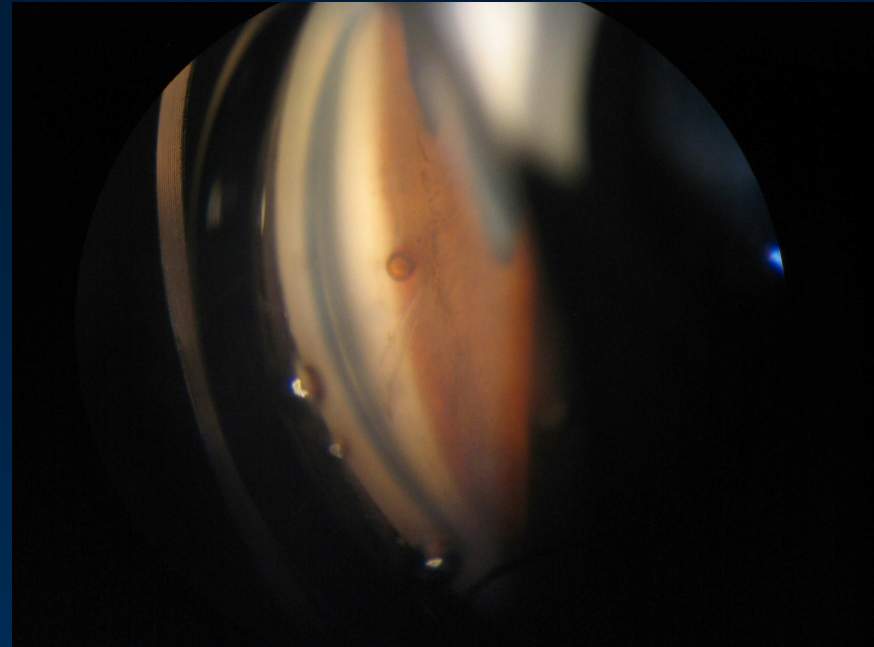
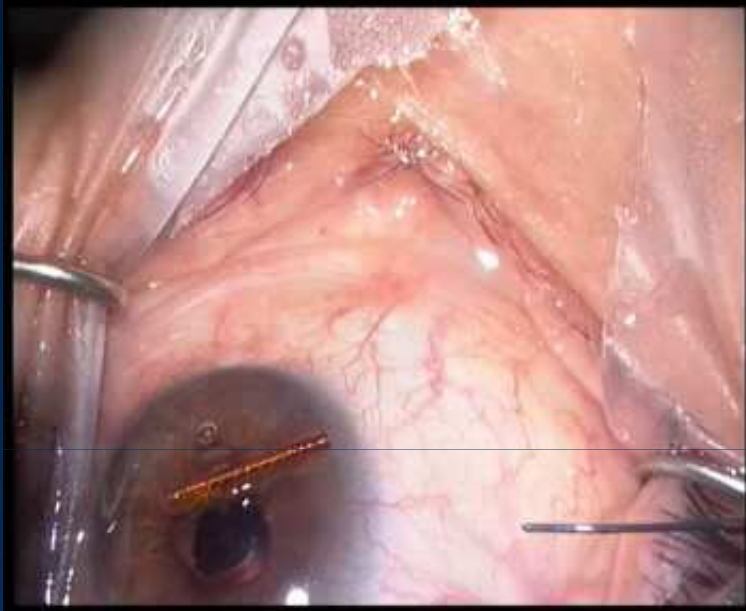
Precedente chirurgia o Laser

**Controindicazione:** Glaucoma chiusura angolare primario e secondario

Anomalie angolari



# CyPass



No studi su riviste indicizzate su PubMed


**ESCRS 09/2010**  
40% riduzione IOP a 6 mesi in 27 Faco+CyPass

No complicanze

## Studio prospettico - 25 occhi - Follow-up 9 mesi

Glaucoma c.s.	9
Cataratta e glaucoma c.s.	6
Ipertono in esiti di trab.	10

Riduzione media IOP	22%
Riduzione farmaci	12%
Sospensione farmaci	16%



### **Complicanze**

Ipoema medio	risoluzione spontanea	1	(4%)
Ipoema moderato	risoluzione chirurgica	1	(4%)

# Take Home Message

Trabeculectomia

*“Gold standard”* chirurgia glaucoma

**Bozza filtrante**

CyPass

**Deflusso  
Uveosclerale**

# Take Home Message

## Complicanze scarse e non gravi

*Precoci: sanguinamento (risoluzione spontanea e non)*

## Tecnica Chirurgica

*Strumenti dedicati*

*Training*

## Efficace nel ridurre la IOP

*Effetti a lungo termine*

*Confronto con trabeculectomia*

A photograph of a large, multi-colored quilted blanket. The blanket features various shades of blue, green, and purple, with a prominent wavy pattern. A red rectangular box is overlaid in the center of the image, containing the word "GRAZIE!" in a bold, red, serif font. The background is a solid, light blue color.

**GRAZIE!**